

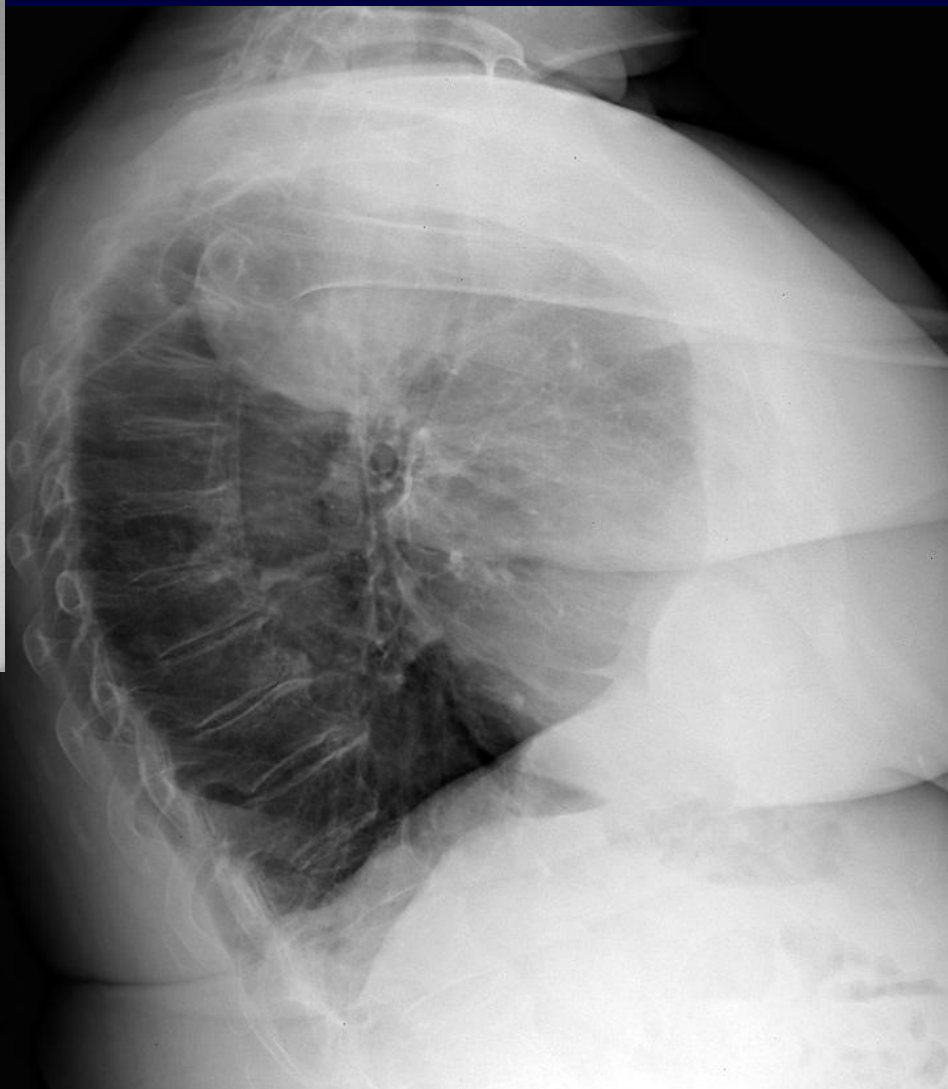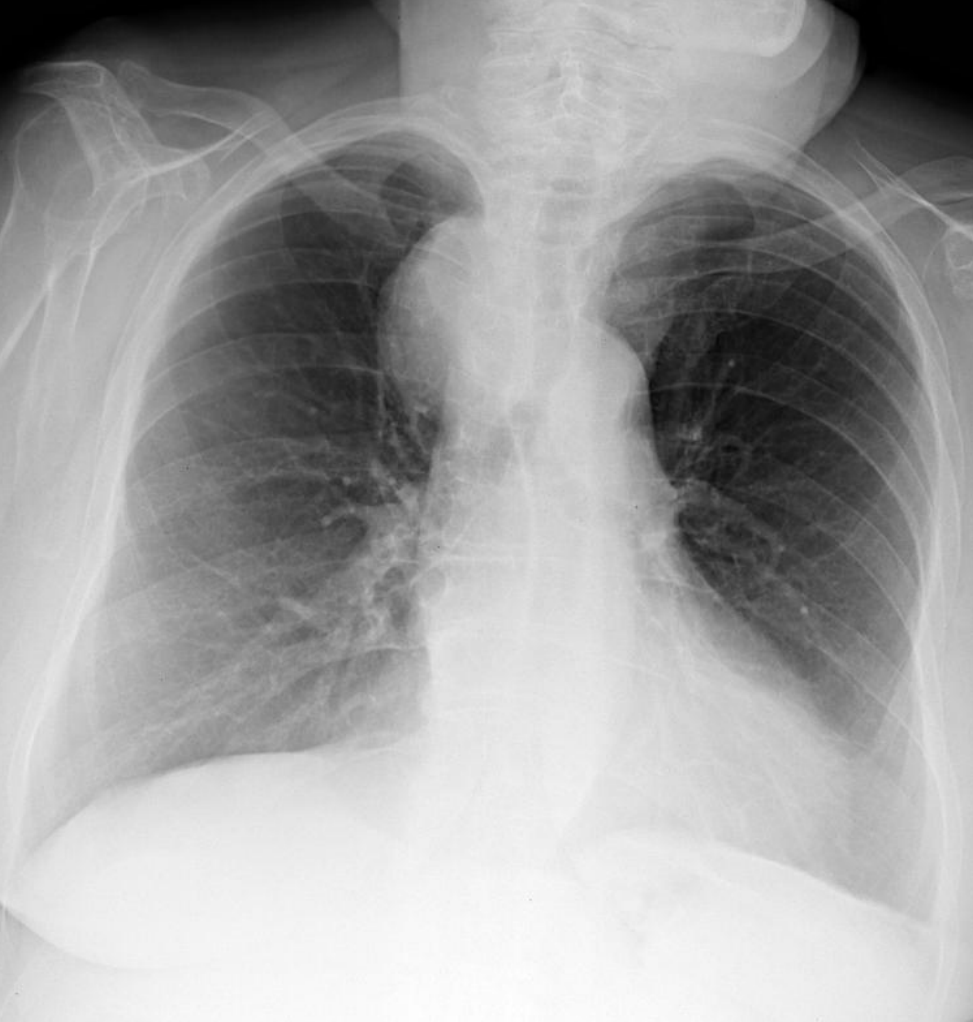


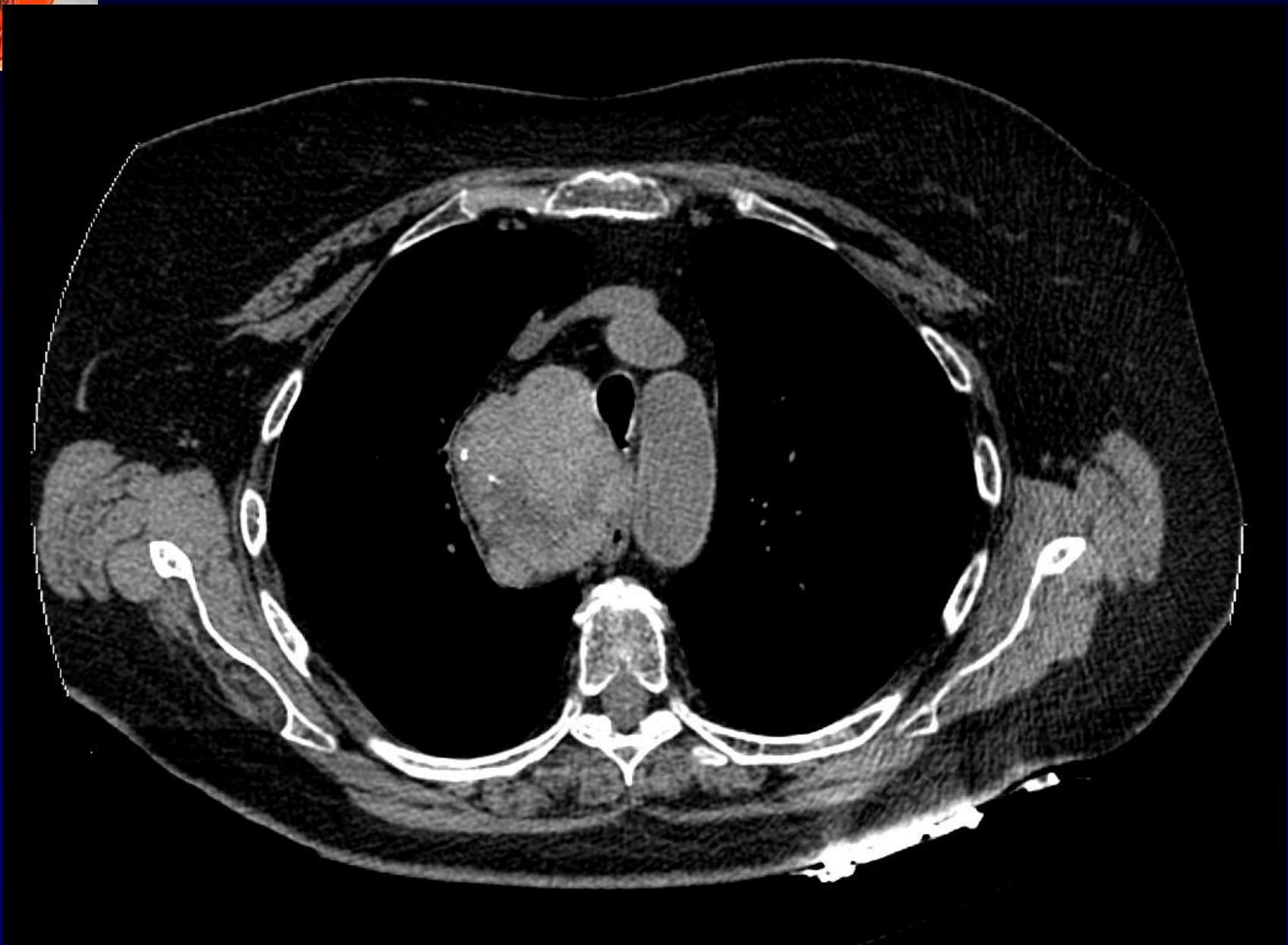
Dr LACOUT Alexis

Femme de 88 ans

Très bon état général

Toux





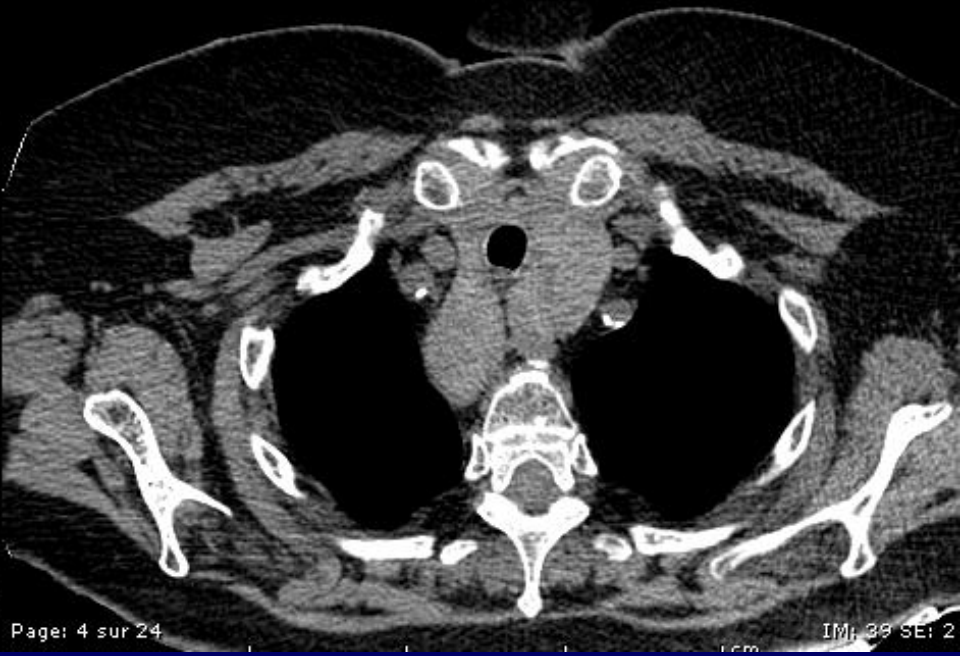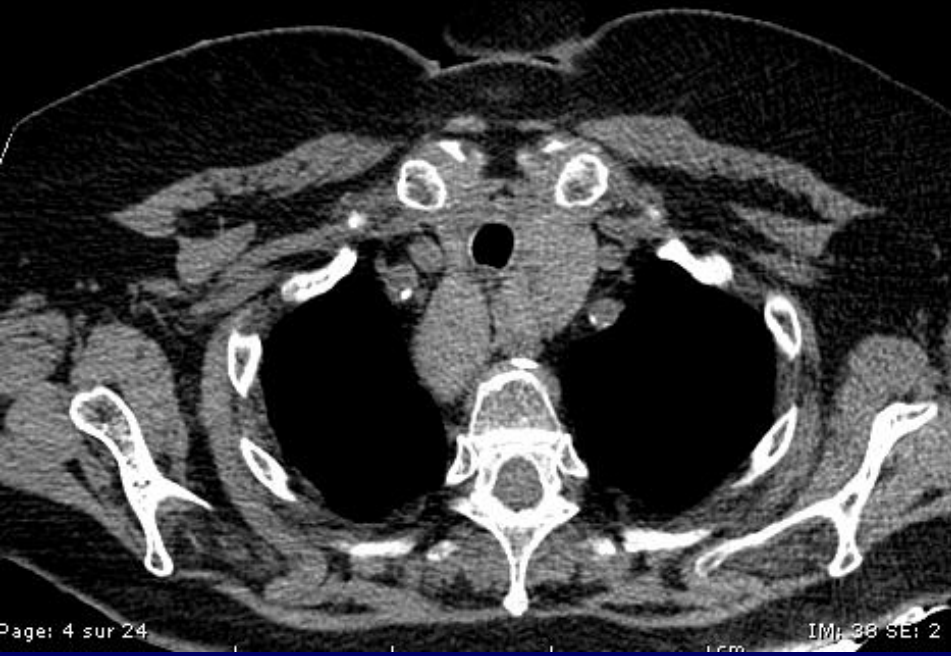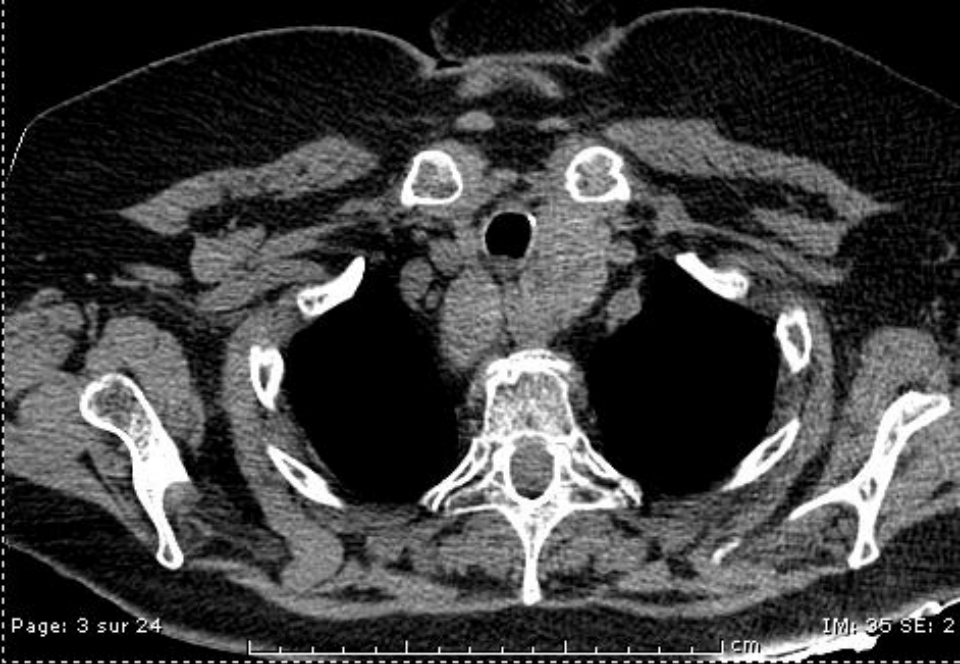


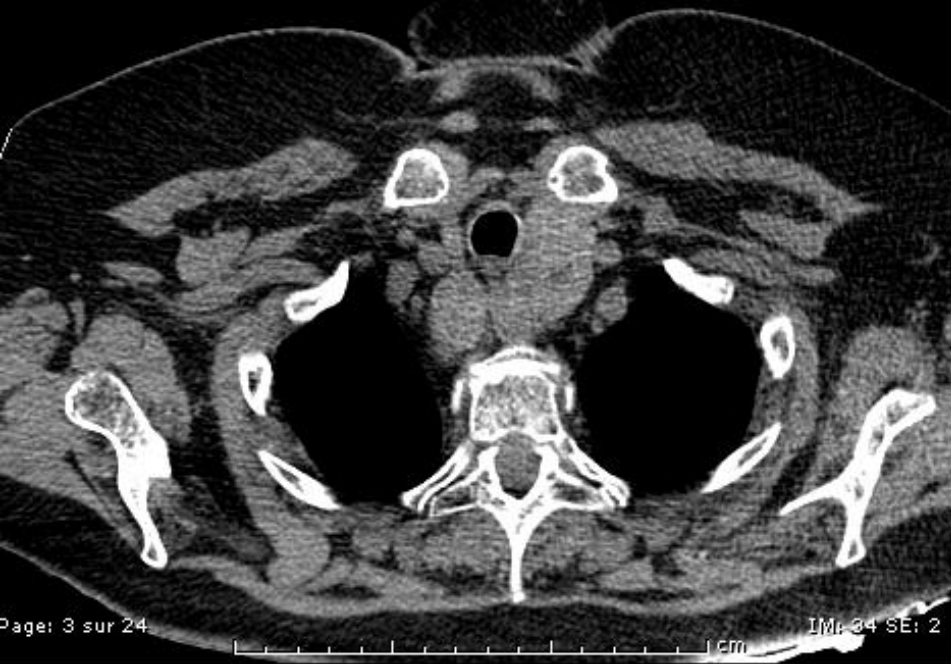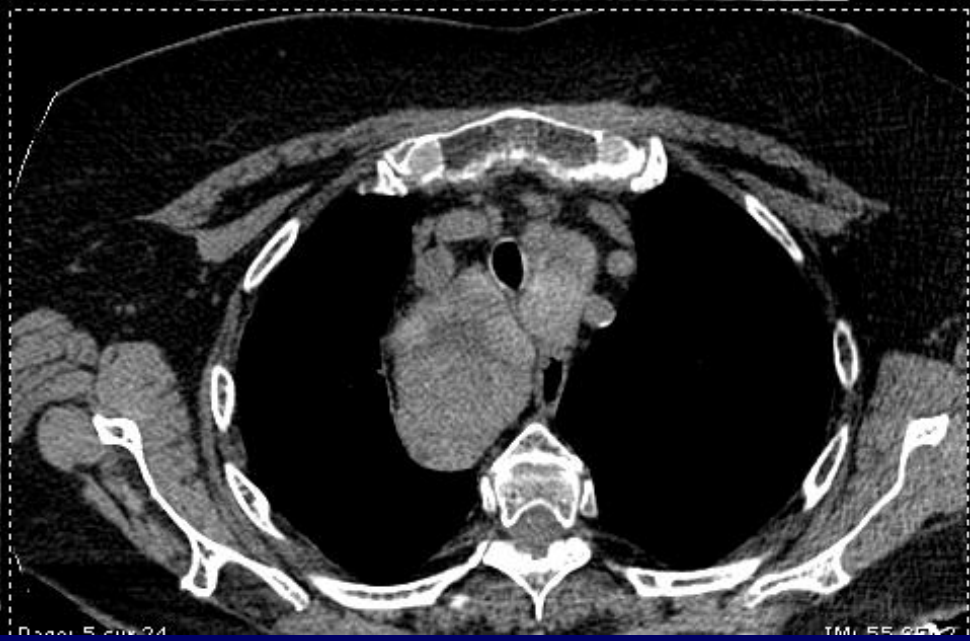
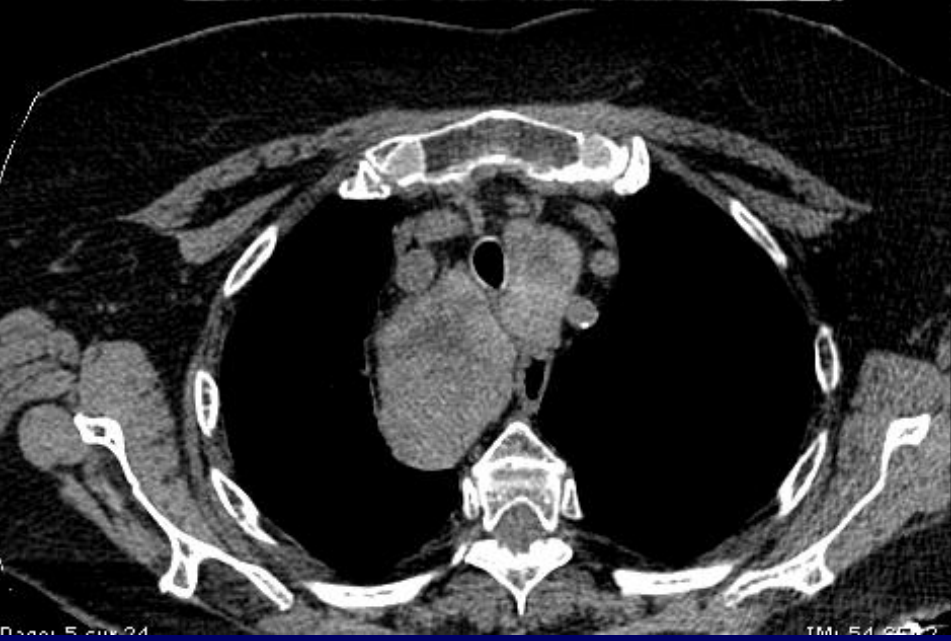
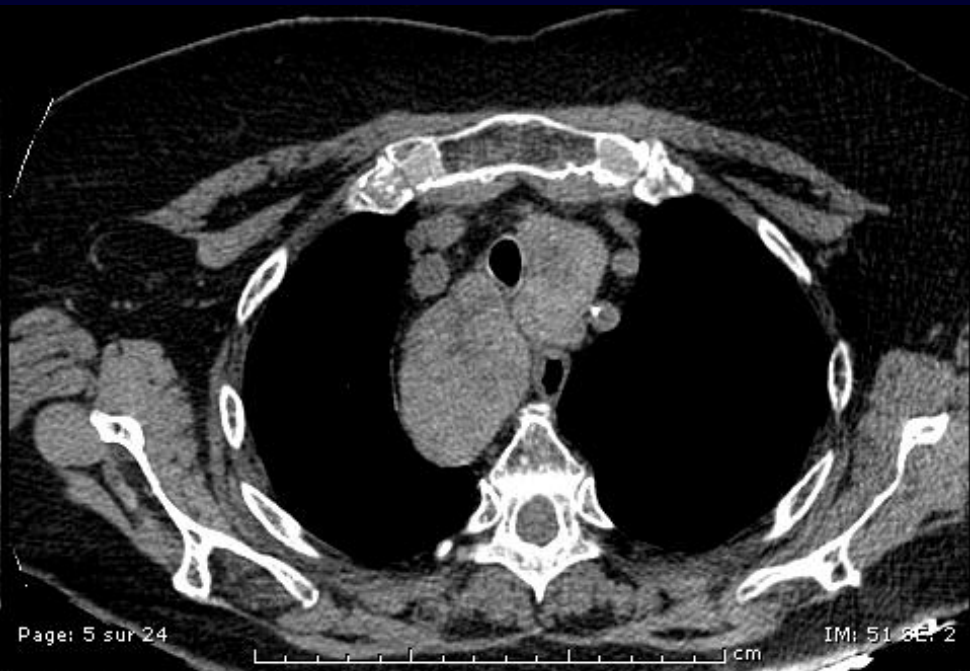
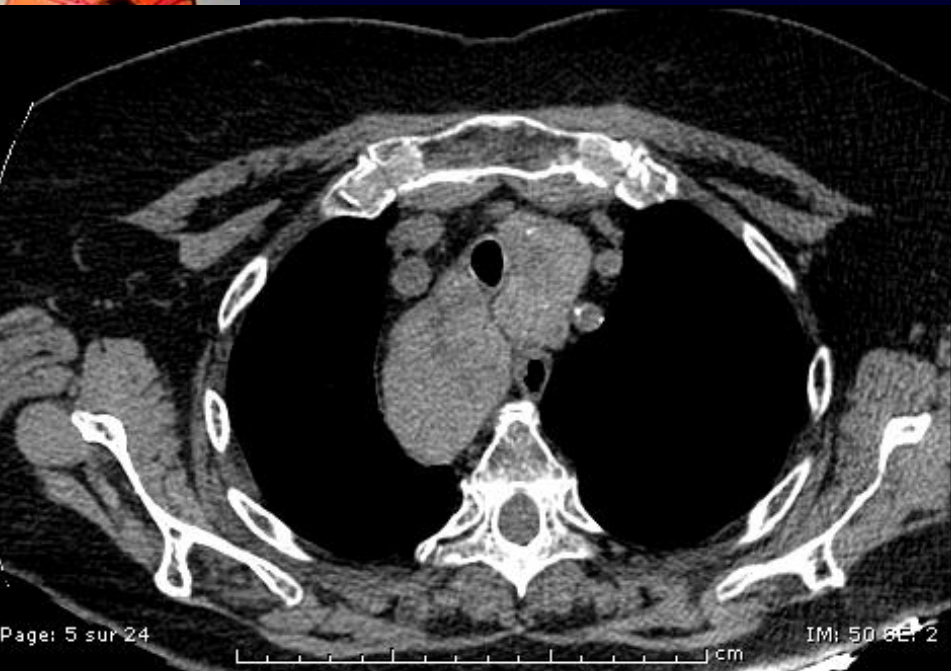
Diagnostic ?

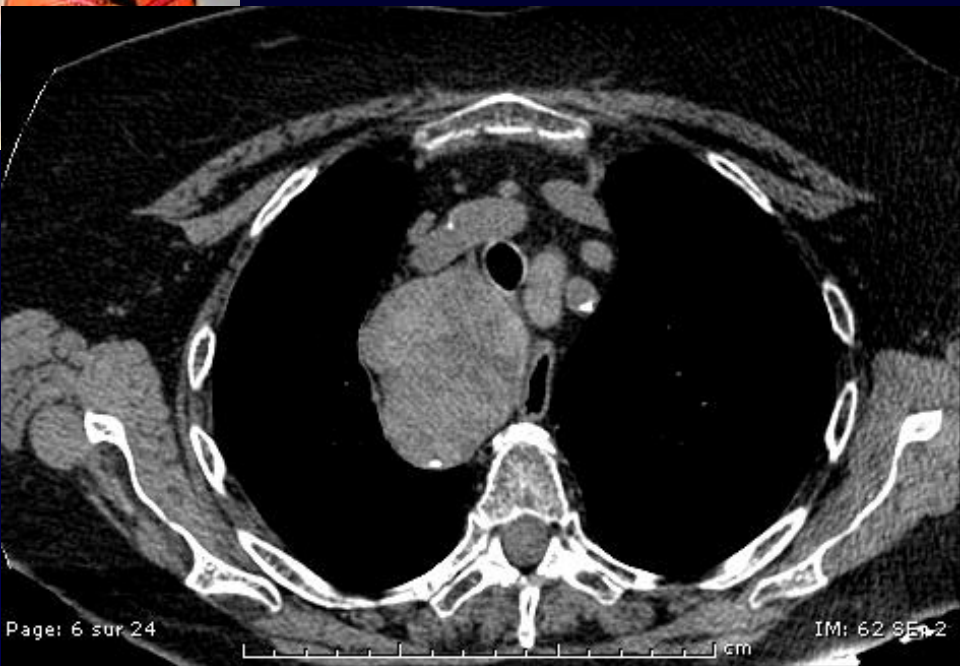


Goitre à prolongement endothoracique

Différent du goitre endothoracique « pur » très rare

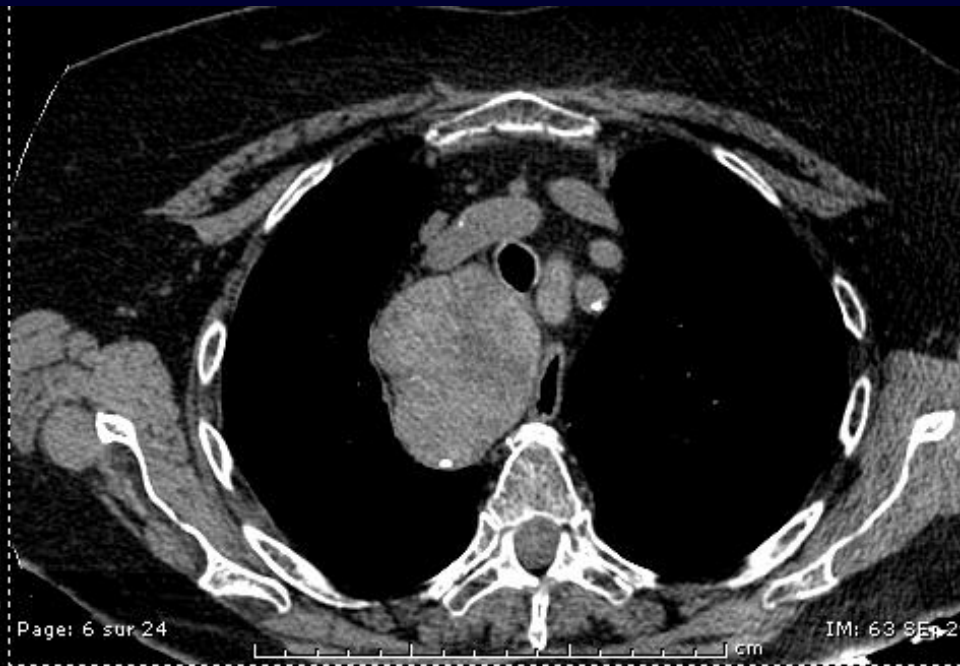






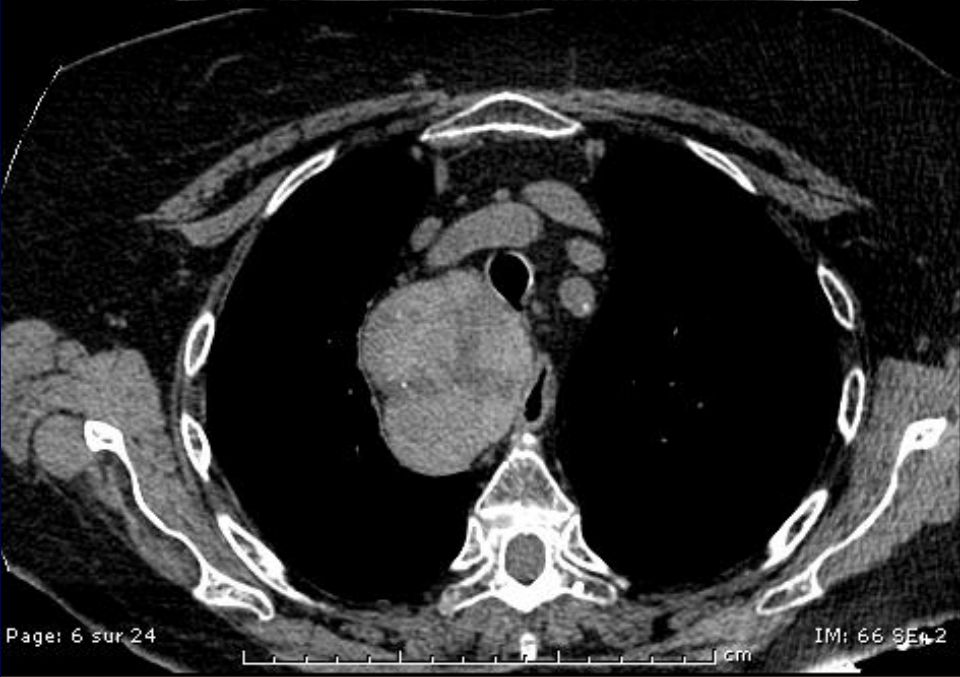Page: 6 sur 24

IM: 62 SE 2



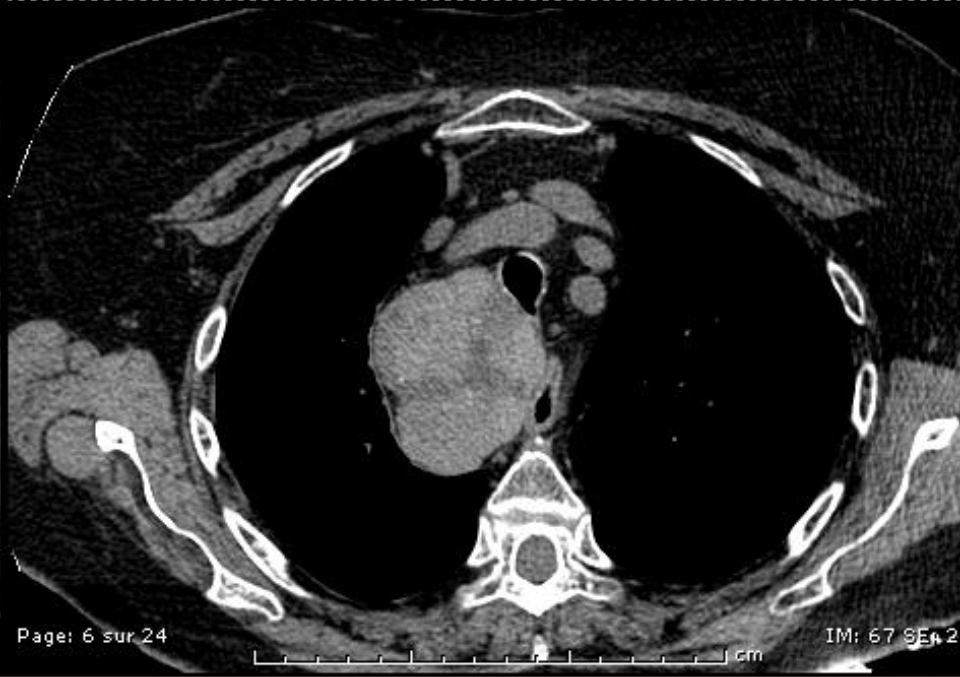Page: 6 sur 24

IM: 63 SE 2



Page: 6 sur 24

IM: 66 SE 2



Page: 6 sur 24

IM: 67 SE 2

